

Gastrointestinal stromal tumour: From the clinic to the molecules

Ilona Hapkova^{1,2,3*}, Florence Bernex⁴, de Santa Barbara P² and Jaroslav Vesely¹

¹ Department of Pathophysiology, Faculty of Medicine and Dentistry, Palacky University, Olomouc, Czech Republic

² INSERM U1046, Université Montpellier 1, Université Montpellier 2, Montpellier, France

³ University of Perpignan Via Domitia, Performance, Health and Altitude Laboratory, EA 4604, Font Romeu, France

⁴ Histological Facility RHEM, IRCM, Institut de Recherche en Cancérologie de Montpellier, Montpellier, F-34298, France

Abstract

Gastrointestinal stromal tumours (GISTs), the most frequent sarcoma in the gastro-intestinal (GI) tract, are highly resistant to conventional chemotherapy and radiotherapy. These tumours have activating mutations in two closely related genes, KIT (75-80%) or/and PDGFRA (5-10%). Targeting these mutated activated proteins with imatinib mesylate has proven efficient in the treatment of GISTs. The median survival after diagnosis of GIST increased from 1.5 to 4.8 years with imatinib treatment. However, resistance to imatinib eventually develops and new-targeted therapies are needed. This paper reviews the medical, clinical and pathological aspects of GISTs based on latest research in human cell lines and animal models.

Keywords: gastrointestinal stromal tumours; interstitial cells of cajal; smooth muscle cells; KIT; platelet-derived growth factor receptor alpha; activating mutation; imatinib mesylate

Introduction

Gastrointestinal stromal tumours (GISTs) are the most common primary mesenchymal neoplasms of the GI tract. They were recognized as distinct molecular entities in 1998 [1-4]. They are thought to derive from differentiated cells similar to gastrointestinal pacemaker cells, interstitial cells of cajal (ICCs) [5]. ICCs are innervated cells associated with Auerbach's plexus that have an autonomous pacemaker function and that coordinate peristalsis throughout the GI tract. It was suggested recently that GISTs either arise from ICCs or share a mesenchymal precursor cell, common of ICCs and smooth muscle cells (SMCs).

GISTs are highly resistant to conventional chemotherapy. However, a targeted therapy is now proposed. GISTs have activating mutation in two closely related receptor tyrosine kinases, KIT (75-80%) or platelet-derived growth factor receptor alpha (PDGFRA, 5-10%). These mutations lead to ligand-independent activation and signal transduction mediated by constitutively activated KIT or PDGFRA. Targeting these activated proteins with imatinib mesylate, a small-molecule tyrosine kinase inhibitor, has proven useful in the treatment of recurrent or metastatic GISTs and is now being tested as adjuvant or neoadjuvant. However, resistance to imatinib is a

growing problem and other targeted therapies such as sunitinib have been developed [4] to try and overcome that resistance.

Historical overview of GIST

GISTs represent the largest subset of mesenchymal neoplasms of the digestive tract. Over the past 23 years, this group of tumours has emerged from a poorly understood class of neoplasm to a well-defined tumour entity. On the basis of light microscopic descriptions in the 1930's to 1950's, stromal tumours of the GI tract were regarded as neoplasms of smooth muscle origin. The first accurate description of mesenchymal

***Corresponding author:** Ilona Hapkova, Department of Pathophysiology, Faculty of Medicine and Dentistry, Palacky University, Olomouc, 775 15, Czech Republic. Tel.: 00420 585632518; Fax: 00420 585632517; Email: ilona.hapkova@upol.cz

Received 13 November 2013 Revised 12 February 2014 Accepted 20 February 2014 Published 28 February 2014

Citation: Hapkova I, Bernex F, Barbara PDS, Vesely J (2014) Gastrointestinal stromal tumour: From the clinic to the molecules. J Cancer Res Ther 2:54-67. doi:10.14312/2052-4994.2014-8

Copyright: ©2014 Hapkova I, et al. This is an open-access article distributed under the terms of the Creative Commons Attribution License, which permits unrestricted use, distribution and reproduction in any medium, provided the original author and source are credited.

neoplasms was published in 1941 [6]. They were most often classified as leiomyomas, leiomyosarcomas, leiomyblastomas or bizarre leiomyomas [7, 8]. However, with the advent of electronic microscopy in the late 1960's and early 1970's, it appeared that only a few of them have convincing ultrastructural evidence of smooth muscle differentiation [9, 10]. Furthermore, the application of immunohistochemistry, starting in the 1980's, clearly demonstrated that many of these tumours lack the features of smooth muscle differentiation, which supported the electron microscopic evidence [10, 11]. The term "stromal tumour" introduced in 1983 by Mazur and Clark, was not widely accepted until the early 1990's, when it was discovered that most stromal tumours arising in the gastrointestinal tract express CD34 [12, 13].

The recognition of the central role of KIT mutations in the pathogenesis of GISTs [14] and in most cases the associated expression of KIT in these tumours provided a reproducible genotypic and phenotypic marker [5]. Therefore KIT (CD117 in the standardized terminology of leucocyte antigens) expression has emerged as a marker for discriminating GISTs from other mesenchymal gastrointestinal neoplasms. Some authors have regarded immunoreactivity for KIT as definition of GISTs [1, 15]. In 2003, Heinrich and colleagues additionally identified platelet-derived growth factor receptor alpha (PDGFRA) mutations as an alternative pathogenetic event in GISTs lacking KIT mutations [16]. To date, approximately 85% of GISTs are reported to harbour activating mutations in KIT or in PDGFRA [4, 17]. Increased understanding of GIST biology has made this tumour merits and limitations of so-called targeted therapeutics.

Epidemiology

The true incidence of GISTs is difficult to determine, as GISTs have only been properly recognized and uniformly diagnosed as an entity since the late 1990's. However, the incidence of GIST is estimated to be approximately 10-20 per million people, per year. About 30-50% of GISTs become malignant and metastases are observed in 50% of cases following initial surgical resection [18]. Recent population-based studies performed in Sweden, Holland, France and Iceland found incidences of 14.5, 12.7, 15 and 11 cases per million people per year [19, 20]. The annual European ASR (age-standardized rate) and World ASR were respectively 4.4 and 3.1 per million people. These findings would translate into an annual incidence in Europe of around 8,000-9,000 cases and in the USA of around 4,000-5,000 cases per year [3]. Nevertheless, the prevalence of GIST is probably higher, as many patients live with the disease for many years or develop small GISTs only detected at autopsy or in the course if a gastrectomy performed for other reasons. GISTs typically occur in older individuals over 50 years of age. The median ages at diagnosis in the largest series of GISTs in different locations ranged between 55 to 65 years. GISTs are rare before the age of 40. Paediatric GISTs are observed however, but remain rare compared to the

adult form [1]. Some series show a male predominance, while others show a balanced gender distribution [21]. Currently there are no known elements suggesting an association with geographic location, ethnicity, race or occupation [22]. The stomach is the most common location of GIST (50-60%) followed by the small intestine (20-30%). 5 to 10% of GISTs arise in the colon or rectum, and less than 5% are located in the oesophagus [3, 4]. Less common locations are outside of the GI tract, like the mesentery, retroperitoneum and omentum. Rare cases have been reported in the gallbladder, pancreas, liver and urinary bladder. In cases, where GISTs occur outside the GI tract, the tumours are identified as extra-gastro intestinal stromal tumours (EGISTs) [1].

Clinical and pathological aspects

Clinical features

The clinical presentation of GISTs is erratic. Clinical symptoms associated with GISTs include abdominal pain, fatigue, dysphagia, satiety and obstruction. The patients may present with chronic GI bleeding (causing anaemia) or acute GI bleeding, caused by erosion of the gastric or bowel mucosa. Rupture of GIST into the abdominal cavity is rare and abuses life threatening intraperitoneal haemorrhage. No more than 70% of patients are symptomatic, while 20% are asymptomatic and, in 10% of cases, the lesions are detected at necropsy. The median tumour size in each of these categories was reported 8.9, 2.7 and 3.4 cm [23]. Small GISTs are mostly incidental findings in endoscopy, surgery or radiologic investigations for other reasons. In 50% of operated GISTs, metastases arise located in the GI tract, quite often 10-15 years after initial surgery. Therefore long-term follow-up is required. On the other hand, distant metastases most commonly occur in the peritoneum, omentum, mesenteric areas and liver. EGISTs metastases are rare [24]. Lymph nodes metastases are not common in adult GISTs.

Macroscopic features

GISTs present most often as well-circumscribed, highly vascular tumours associated with the stomach or the intestine. On gross examination, these tumours appear fleshy pink or tan-white and may show haemorrhagic foci, central cystic degenerative changes or necrosis [25].

Microscopic features and immunohistochemical markers

Microscopic evaluation reveals three principal subtypes of GIST depending on the cytomorphology. Spindle cell GISTs, accounting for approximately 70% of cases, are made up of cells arranged in short fascicles or whorls, with a pale eosinophilic fibrillary cytoplasm, an ovoid nucleus, and ill-defined cell borders, often with a syncytial appearance. GISTs with epithelioid cell morphology, accounting for approximately 20% of cases, are arranged in sheets and nests, made up of round cells with a large eosinophilic to clear cytoplasm. Approximately 10% of GISTs show mixed morphology, with both spindle and epithelioid

cells [2, 26]. Occasional tumours have neuroendocrine-like features that resemble paraganglioma or carcinoid. A signet ring-like variant has also been described [27].

Obtaining adequate tumour tissue material for definitive diagnosis prior surgical resection has been challenging. Because these tumours tend to be soft and friable, biopsy may cause rupture of the tumour and thus increase risk of tumour dissemination. Tumours may have substantial histological variation, which requires a broad differential diagnosis. Immunohistochemistry is often needed to confirm the diagnosis. Approximately 95% of the tumours are positive for KIT (CD117). In general, KIT staining in GISTs is strongly and diffusely positive, but is not necessarily uniform across different regions of the same tumour, staining may appear in a cytoplasmic (most common), membranous, or as a concentrated dot-like perinuclear pattern. Some cases show combinations of these patterns. Epithelioid GISTs tend to have a weaker and patchier staining pattern than spindle cell GISTs [28].

Other commonly expressed markers include CD34 (expressed in 60-70% of tumours), h-caldesmon (60%), alpha smooth muscle actin (αSMA; 30-40%), S100 (5%), desmin (1-2%) and keratin (1-2%) [29]. DOG1 also known as TMEM16A or ANO1 is a calcium-dependent, receptor-activated chloride channel protein and seems to be expressed in GIST independently of the type of mutation [30]. In a study of 1168 cases of GISTs, the overall sensitivity of DOG1 and KIT was nearly identical (94.4% and 94.7%, respectively) and a high concordance was found between DOG1 and KIT immunohistochemistry (92.3% positivity for both) [31]. RNA-Binding protein with multiple splicing 2 (RBPMS2), an early marker of gastrointestinal SMC embryonic precursors, was significantly highly expressed in GIST samples, particularly in high risk tumours compared to control gastrointestinal tissues [32].

However, about 5% of GISTs are truly negative for detectable KIT expression, the so-called “KIT-negative GISTs” [33]. In a proportion of these KIT-negative GISTs, the genotypic analysis shows mutations in PDGFRA, in 10-15% of cases [34]. Many of these PDGFRA-mutant GISTs have an epithelioid morphology. Immunostaining with PDGFRA antibody has been shown in this particular setting to be helpful to discriminate between KIT-negative GISTs and other gastrointestinal mesenchymal lesions [35]. V600E BRAF mutations have been identified in 7% of adult GIST patients lacking KIT or PDGFRA mutations (known as wild-type GISTs). The BRAF-mutated GISTs show predilection for small bowel location and a high risk of malignancy. KIT is consistently over-expressed in these cases but there are no distinctive microscopic features that would differentiate them from KIT-mutated GISTs [36]. GISTs lacking KIT or PDGFRA mutations are a heterogeneous group, some of which have alternations in H-RAS and N-RAS genes or in the genes of succinate dehydrogenase complex, but are much more rare [4].

Prognostic factors

The prognosis of primary tumours has been studied intensively. Tumour size and mitotic activity were two major factors in the risk stratification system originally proposed by Fletcher and colleagues. A tenet of which was that almost all gastrointestinal stromal tumours have malignant potential [18]. Table 1 shows a revised version of the risk assessment scheme, based on several large series published by Miettinen and colleagues [2]. This scheme includes anatomic site as a factor, since small bowel stromal tumours carry a higher risk of progression than gastric stromal tumours of similar size and mitotic activity. Immunohistochemical markers may be of importance in predicting the malignant behaviour of GISTs. Increased expression of cell cycle markers (PCNA, MIB-I or Ki-67) have been linked to a less favourable prognosis in larger studies [37].

Table 1 Risk stratification of primary GIST by Mitotic index, size and site.

Tumour parameters		Risk for progressive disease* (%), Based on site of origin			
Mitotic Rate	Size	Stomach	Jejunum/Ileum	Duodenum	Rectum
	≤ 2 cm	None (0%)	None (0%)	None (0%)	None (0%)
	> 2, ≤ 5 cm	Very low (1.9%)	Low (4.3%)	Low (8.3%)	Low (8.5%)
≤ 5 per 50 HPF	> 5, ≤ 10 cm	Low (3.6%)	Moderate (24%)	Insufficient data	Insufficient data
	> 10 cm	Moderate (10%)	High (52%)	High (34%)	High (57%)
> 5 per 50 HPF	≤ 2 cm	None†	High†	Insufficient data	High (54%)
	> 2, ≤ 5 cm	Moderate (16%)	High (73%)	High (50%)	High (52%)
	> 5, ≤ 10 cm	High (55%)	High (85%)	Insufficient data	Insufficient data
	> 10 cm	High (86%)	High (90%)	High (86%)	High (71%)

Data are based on long-term follow-up of 1055 gastric, 629 small intestinal, 144 duodenal, and 111 rectal GISTs. HPF = high-power field. Adapted from Miettinen & Lasota (2006) [2].

Abbreviations: *=Defined as metastasis or tumour-related death; †=Denotes small numbers of cases.

Paediatric GISTs

Approximately 1-2% of GISTs occur in the paediatric age group. Paediatric GISTs are associated with a marked female predominance. They are preferentially located in stomach, and show mainly epithelioid morphology. Although these tumours consistently express KIT, the majority lack KIT or PDGFRA mutations [38]. Unlike adult GISTs, these tumours quite often spread to lymph nodes. Interestingly, paediatric KIT-wild-type GISTs lack the typical cytogenetic deletions seen in adult KIT-mutant GISTs and progress to malignancy without acquiring large-scale chromosomal aberrations [39]. The difference between paediatric and adult GISTs of the stomach is further demonstrated by their separate clustering by gene expression profiling. It is very likely that these tumours are a separate clinicopathologic entity. In the paediatric GIST group, time to tumour progression was significantly longer on sunitinib than on prior imatinib treatment, indicating that this patient group might benefit from sunitinib as first-line treatment [39].

Oncogenic kinase mutations in GIST

Receptor tyrosine kinase

Since the discovery of the first receptor tyrosine kinase (RTK) more than a quarter of a century ago, many members of this family of cell surface receptors have emerged as key regulators of critical cellular processes, such as proliferation and differentiation, cell survival and metabolism, cell migration and cell cycle control [40].

Humans have 58 known RTKs, which fall into twenty subfamilies. All RTKs have a similar molecular architecture, with a ligand-binding region in the extracellular domain, a single transmembrane helix, and a cytoplasmic region that contains the protein tyrosine kinase (TK) domain plus additional carboxy (C-) terminal and juxtamembrane regulatory regions. The overall topology of RTKs, their mechanism of activation, and key components of the intracellular signalling pathways that they trigger are highly conserved in evolution from the nematode *Caenorhabditis elegans* to humans, which is consistent with the key regulatory roles they play. Furthermore, numerous diseases result from genetic changes or abnormalities that alter the activity, abundance, cellular distribution, or regulation of RTKs. Mutations in RTKs and aberrant activation of their intracellular signalling pathways have been causally linked to cancers, diabetes, inflammation, severe bone disorders and arteriosclerosis. These connections have led to the development of a new generation of drugs that block or attenuate RTK activity [41]. Type III receptor tyrosine kinase is a family of kinases sharing a structure that consists of five extracellular (EC) immunoglobulin-like (Ig-like) domains, a single transmembrane domain and a split kinase domain with a juxtamembrane (JM) domain, and two cytoplasmic kinase domains (TK I: ATP-binding pocket; and TK II: kinase activation loop), shown in Figure 1 [42]. KIT is a member of this family that includes PDGFRA and PDGFRB, as well as macrophage colony-stimulating-factor 1 receptor (CSF1R) and fms-like tyrosine kinase 3 (FLT3) [43].

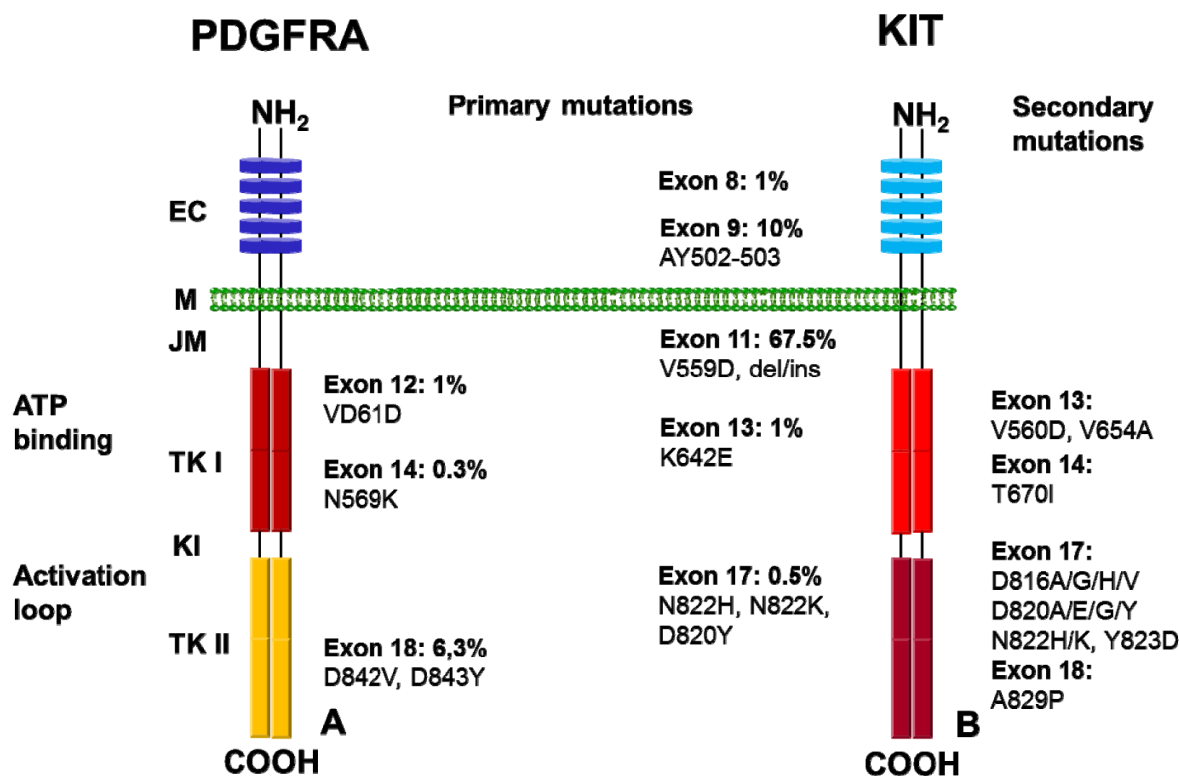


Figure 1 PDGFRA and KIT schematic structure. (A) Primary oncogenic mutation in PDGFRA. (B) Distribution of primary and secondary mutations in KIT. Abbreviations: EC= Extracellular domain; M= Membrane; JM= Juxtamembrane domain; TK I= Tyrosine kinase domain I; KI= Kinase insert; TK II= Tyrosine kinase domain II [2 - 4, 41].

KIT, a 145-kDa transmembrane glycoprotein is located on the proximal long arm of chromosome 4, and is the normal cellular homologue of the viral oncoprotein v-KIT. KIT is normally expressed by hematopoietic progenitor cells, mast cells, primordial germ cells and mature cells, melanoblasts and melanocytes, ICCs, and also by various human cell tumours [44]. KIT ligand, or stem cell factor (SCF) is a homodimer of two four-helix bundles. Each SCF molecule binds to one molecule of KIT through contacts with the first three (of five) Ig-like domains in the KIT extracellular region. Binding of SCF to KIT results in receptor homodimerization, activation of the tyrosine kinase activity, and resultant phosphorylation of several downstream signalling substrates known to promote cell growth and survival [41]. Alternatively, oncogenic KIT mutations result in ligand-independent kinase activation [3, 45]. As first reported by two groups in 1998, 95% of GISTs express KIT, and the immunohistochemical reaction remains a crucial diagnostic marker for most GISTs. At the same time, Hirota and colleagues published their ground-breaking discovery of KIT mutations in GISTs [5, 14]. It is now established that 70-80% of GISTs harbour a KIT mutation, leading to the constitutive activation of the kinase. Therefore these mutations are a clinically important therapeutic target in GISTs [14].

The most common primary mutations in KIT affect the juxtamembrane domain that is encoded by exon 11. Two-thirds of GISTs harbour mutations in exon 11, which disrupt the normal juxtamembrane secondary structure that prevents the kinase activation loop from swinging into the active conformation [46]. These mutations include in-frame deletions, insertions and substitutions, or combinations of these. The deletions are associated with a shorter progression-free and overall survival in comparison to the other exon 11 mutations. In particular, deletions involving codon 557 and/or codon 558 are associated with malignant behaviour [47]. Aside from exon 11 mutations, between 7% and 10% of GISTs have a mutation in an extracellular domain that is encoded by exon 9. These mutations are thought to mimic the conformational change the KIT receptor undergoes when SCF is bound. Importantly, the kinase domain in exon 9-mutant KIT is essentially the same as in wild-type KIT, and this has an effect on inhibitor sensitivity. Also important is that these mutations occur in tumours that arise in the intestine, but are rarely seen in the stomach [48]. Mutations in the activation loop (which is encoded by exon 17) of the kinase are uncommon, and stabilize the active conformation. Mutations in the ATP-binding region encoded by exon 13 (such as K642E), are also uncommon [48].

Secondary mutations are concentrated in two regions of the KIT kinase domain. One target is the ATP-binding pocket, encoded by exons 13 and 14, the part of the protein that directly interferes with drug binding. The other target is the activation loop, where mutations can stabilize KIT in the active conformation and thereby

hinder drug interaction. By contrast, the secondary ATP-binding pocket mutations do not cause intrinsic kinase activation, detail shown in Figure 1 [49, 50].

By immunohistochemistry, KIT is detected at the membrane surface of GIST cells, but strong staining is also commonly observed in the cell cytoplasm and is sometimes concentrated in a perinuclear, dot-like pattern. Furthermore, mutant KIT that has been further modified with a Golgi-localization motif retains its ability to activate downstream signalling, raising the interesting possibility that signalling from mutant KIT may occur directly from the Golgi. Tumour extracts from KIT-mutant GISTs demonstrate evidence of activation of downstream signalling pathways, including the MAPK pathway (which consists of RAF, MEK and MAPK), the PI3K-AKT pathway and signal transducer and activator of transcription 1 and 3 (STAT1 and STAT3), and p70/85S6K [17]. In contrast, the JNK and STAT5 pathways are not activated [16]. Using specific inhibitors of KIT, MEK1/2, PI3K or mTOR, it has been shown that activation of the PI3K/mTOR, but not the MEK/MAPK pathway, is essential to KIT-mediated oncogenic signalling in GISTs. Correspondingly, selective inhibitor of the PI3K/mTOR pathway reduces proliferation and increases apoptosis [26].

Platelet-derived growth factor receptors (PDGF-R) are RTK for members of the platelet-derived growth factor (PDGF) family. PDGF-R are important factors regulating cell proliferation, cellular differentiation, cell growth, development and many diseases including cancer [51]. These two receptor isoforms (PDGFRA and PDGFRB) dimerize upon binding the PDGF dimer, leading to three possible receptor combinations, namely - $\alpha\alpha$, - $\beta\beta$ and - $\alpha\beta$. The α -receptor binds all three forms of PDGF, whereas the β -receptor binds only PDGF $\beta\beta$ [52]. PDGFRA is normally expressed in the digestive musculature into fibroblast-like cells, cells closely associated to ICC and myenteric Ganglionic cells (Kit-negative fibroblast-like cells express *Pdgfra* in the murine GI musculature) [53].

PDGFRA is activated in approximately 8% of GISTs that harbour mutations in the PDGFRA juxtamembrane domain (encoded by exon 12), the ATP-binding domain (encoded by exon 14) or the activation loop (encoded by exon 18). Consistent with their extensive functional overlap, KIT and PDGFRA mutations are mutually exclusive in GISTs (Figure 1). Altogether, about 85 % of GISTs have mutation in one of these two kinase genes [3, 4].

Other driver mutations

Approximately 15% of GISTs do not have a detectable mutation in either KIT or PDGFRA. In other aspects these so-called "wild-type" GISTs are clinically indistinguishable from KIT- or PDGFRA-mutant GISTs, since they have an identical morphology, express high levels of KIT and occur anywhere in the GI tract. Phosphorylated KIT is detectable in these tumours, suggesting that KIT is still activated [33], but the mechanism of this activation is unclear.

However, recent studies have shown that wild-type GISTs are a heterogeneous group and display various oncogenic mutations. For example, the BRAF V600E substitution that is common in papillary thyroid carcinoma and melanoma is present in up to 13% of wild-type GISTs [54]. H-RAS and N-RAS mutations also occur, but are much more rare. Because BRAF and RAS are constituents of the MAPK signalling cascade, they can result in KIT-independent growth stimulation, and are possible causes of resistance to KIT and PDGFRA kinase inhibitors.

The Carney stratakis syndrome involves 2 of the 3 conditions required for Carney's triad: GIST and paraganglioma (but it does not include pulmonary chondroma) [55]. It is associated with loss-of-function mutations within the succinate dehydrogenase (SDH) genes. Defects in the SDH complex of respiratory chain complex II have recently been identified in wild-type GISTs. This complex, comprised of four subunits (SDHA, SDHB, SDHC and SDHD), oxidizes succinate to fumarate as part of the mitochondrial Krebs's cycle. Germline mutations in SDHB, SDHC or SDHD increase the risk not only of development of GIST, but also of development of paragangliomas. Interestingly, some wild-type GISTs lacking SDH mutation show either a marked reduction or an absence of SDHB expression by immunohistochemistry, and a corresponding loss of respiratory chain complex II enzymatic activity [56]. However, SDHB, SDHC and SDHD mRNA levels are comparable to those in KIT-mutant GISTs, which suggests that SDHB down regulation occurs at the level of protein translation. The tumorigenic mechanisms of SDH loss-of-function in GISTs remain to be studied, but it is possible that the resulting elevation of succinate levels may negatively regulate prolyl hydroxylase. This enzyme is an important regulator of hypoxia-inducible factor 1 α (HIF1 α) levels, and HIF1 α is a transcriptional activator of insulin-like growth factor 2 (IGF2) and vascular endothelial growth factor (VEGF). In keeping with this model, VEGF expression is higher in wild-type GISTs than in KIT-mutant GISTs [57].

Approximately 50% of wild-type GISTs show high expression of insulin-like growth factor 1 receptor (IGF1R). Whether this correlates with SDH complex activity remains to be determined, but it is possible that an IGF autocrine loop is sustained in part by loss of SDH and upregulation of IGF2 expression [58]. IGF1R signals through both the MAPK and the PI3K-AKT pathways.

It is estimated that 7% of patients with neurofibromatosis type I (NF1) develop one or more GISTs. Most arise in the small intestine and they do not readily metastasize. The majority of these GISTs are wild-type for KIT and PDGFRA, but they show either somatic mutation or loss of the remaining wild-type NF1 allele [59].

Unlike GISTs in adults, those that arise in paediatric patients (approximately 1-2% of all GISTs) are rarely positive for KIT or PDGFRA mutations. These tumours, which often metastasize but tend to grow slowly, have

a different gene expression signature from that of adult type GISTs [60].

Chromosomal and molecular alterations during GIST progression

Although oncogenic kinase mutations assume an important role in the development of GISTs, other genetic events are important in their clinical progression. Approximately two-thirds of GISTs demonstrate either monosomy of chromosome 14, or partial loss of 14q [16]. Interestingly, these chromosome 14 abnormalities are observed in both KIT-mutant and in PDGFRA-mutant GISTs. Loss of the long arm of chromosome 22 is observed in approximately 50% of GISTs [16, 61]. Losses on chromosomes 1p, 9p, 11p and 17p are less common than 14q and 22q losses, but are more significantly associated with malignancy. Losses on chromosomes 10, 13q and 15q have also been reported in GISTs. Gain on chromosome 8q, 3q and 17q are associated with metastatic behaviour [62]. Ylipää and colleagues conducted a comprehensive, high-resolution, whole-genome array comparative genomic hybridization analysis to map the recurrent copy number aberrations in 42 GISTs. They also proposed a new tumour progression genetic staging system termed genomic instability stage to complement the current GIST staging system, based on tumour size, mitotic index, and KIT and/or PDGFRA mutations [62].

Human GIST cell lines

To examine the relevance of KIT signalling in the pathophysiology of GIST, Tuveson and colleagues established a GIST cell line, GIST882, from a patient with metastatic GIST. Both the primary GIST and the GIST882 cell line expressed KIT allele with an exon 13 missense mutation, resulting in a single amino acid substitution, K642E, in the proximal part of the split TK domain. This GIST cell line was first reported, and to this day human GIST882 imatinib sensitive cell line is used [63]. In 2002, Taguchi and colleagues published study of another GIST cell line, GIST-T1. It has a heterogenic 57-bp deletion in exon 11 and produces a mutated KIT, which results in its constitutive activation [64].

Inhibition of KIT oncoproteins by imatinib induces a clinical responses in most GIST patients. However, many patients eventually develop resistance to imatinib due to secondary KIT mutations. Heat shock protein 90 (HSP90) protects KIT oncoproteins from proteasome-mediated degradation. Bauer and colleagues did preclinical validations of the HSP90 inhibitor, 17-allylamino-18-demethoxy-geldanamycin (17-AAG), in an imatinib sensitive GIST cell line (GIST882) and in novel imatinib-resistant GIST lines that are either dependent on (GIST430 and GIST48) or independent of (GIST62) KIT oncoproteins [65].

A GIST cell line with the PDGFRA D842V mutation was also produced and characterized [66].

Animal models in GIST research

In 2005, a mouse model of familial GIST was developed by a knock-in gene targeting strategy, which introduced a Kit K641E mutation, originally identified in sporadic human GISTs and in the germ line of GIST syndrome patients. Homozygous and heterozygous Kit K641E mice develop gastrointestinal lesions with complete penetrance and all Kit K641E homozygotes die by the age of 30 weeks due to GI obstruction associated with the presence of hyperplastic ICCs or GISTs. Heterozygous mice have less extensive ICC hyperplasia and smaller GISTs, suggesting a dose-response relationship between oncogenic activated Kit and ICC proliferation [67]. In addition to ICC hyperplasia and GISTs, homozygous Kit K641E mice show loss-of-function Kit phenotypes, including white coat colour, decreased numbers of dermal mast cells, and sterility. This indicates that, despite its oncogenic activity, the mutant form cannot accomplish many activities of the wild-type gene. Kit K641E reproduces the pathology associated with the familial GIST syndrome and is thus an excellent model to study Kit pathway activation, ICC biology, GIST pathogenesis, and preclinical validations of GIST therapies and mechanisms of drug resistance development [67].

Bernex and colleagues analysed spatial and temporal patterns of c-kit-expressing cells in Kit^{W-lacZ/+} and Kit^{W-lacZ/Kit^{W-lacZ}} mouse embryos [68]. They specifically marked the kit-expressing cells and followed their fate during embryogenesis. Their results indicate that the function of Kit is only required for the postnatal development of the ICC [68]. In 2003, Sommer and co-workers published a study where heterozygous mutant Kit^{V558A} /+ mice reproduce human familial GISTs for the study of the role and mechanisms of Kit in neoplasia [69].

Olson and Soriano generated conditional knock-in mice with mutations in PDGFRA that drive increased kinase activity under the control of the endogenous Pdgfra promoter [70]. In embryos, increased Pdgfra signalling leads to hyperplasia of stromal fibroblasts, which disturbs normal smooth muscle tissue in radially patterned organs. In adult mice, higher Pdgfra signalling also increases connective tissue growth, leading to a progressive fibrosis phenotype in multiple organs. Increased Pdgfra signalling in an Ink4a/Arf-deficient genetic background leads to accelerated fibrosis, suggesting a new role for tumour suppressors in attenuating fibrotic diseases [70].

In addition to the conventional mouse model, various studies were initiated on gastrointestinal neoplasms and GISTs behaviour in the digestive tract of rats, dogs, horses, ibex, guinea pigs, rhesus macaque and chimpanzee [71-75].

Treatment of gastrointestinal stromal tumour

The main treatment for localized GISTs is surgical resection. The goal of surgery is complete gross resection with preservation of an intact pseudocapsule. These

tumours should be handled carefully to avoid tumour rupture, which carries a very high risk of intra-abdominal dissemination. In a large retrospective series, the survival of patients whose complete resection was complicated by tumour rupture was significantly shorter than that of patients who had complete resection without tumour rupture [76]. The risk of relapse following surgical resection may be estimated now using 5 parameters: (1) mitotic rate, (2) tumour size, (3) tumour site, (4) tumour rupture, and (5) the nature of the primary mutation. Risk models based on the first 2, 3, 4, and 5 risk factors have been proposed [77]. These risk models are used by physicians to decide on the timeliness of adjuvant treatment with imatinib. Patients with tumours at high risk of relapse are considered for adjuvant treatment. The threshold level for high risk varies according to the prognostic classification. The physician's decision has also to be adapted to the clinical context (age, comorbidities) and requires a careful discussion with the patient.

Metastases typically present with tumours isolated in the peritoneal cavity or the liver, or both. Historically, the median survival of patients with advanced GISTs was between 10 and 20 months. Before the pre-Tyrosine Kinase Inhibitor (TKI) era, treatment options were extremely limited for patients with unresectable or metastatic gastrointestinal stromal tumours. Indeed, these tumours respond poorly (0%-27%) to conventional cytotoxic chemotherapy agents and radiation therapy.

Targeted therapy of GISTs with imatinib mesylate

Targeted therapy is now the first choice of treatment for GISTs that cannot be completely removed by surgery. Imatinib mesylate (STI571, Gleevec) is a 2-phenylpyrimidine derivative that blocks the binding of adenosine triphosphate to ABL kinase. Developed by Dr. Brian Druker in collaboration with Novartis Pharma, this drug has received worldwide attention for its efficacy against chronic myelogenous leukaemia (CML). The BCR-ABL fusion gene product of the Philadelphia chromosome in CML is responsible for driving tumour proliferation [78]. Imatinib is not entirely specific for ABL and has shown also significant inhibitory activity against related tyrosine kinases ARG (ABL-related kinase), PDGFRA, PDGFRB and KIT. Two important observations made in 1999 suggested that imatinib might be effective against GISTs. The first was that imatinib could block the in vitro kinase activity of both wild-type KIT and a mutant KIT isoform commonly found in GISTs (point mutation in exon 11) [79]. The second observation was that imatinib inhibited the growth of a GIST cell line containing a KIT mutation [80]. Imatinib was well tolerated by the patient, and all cancer-related symptoms disappeared [81].

Imaging of GIST patients is done with structural and functional methods such as contrast-enhanced helical computed tomography (CT) and positron emission tomography (PET) with 18F-fluorodeoxyglucose (FDG) [82]. Although CT shows greater anatomic detail, FDG

PET can reveal small metastases and establish baseline metabolic activity, which can later aid in assessing the response to therapy and is a strong predictor of clinical outcome [83, 84].

Several unrelated clinical studies have evaluated the efficacy of imatinib mesylate at various dose levels. Two randomised, phase III trials were initiated in Europe, Australasia, and North America to compare the efficacy of 400 mg of imatinib given either once or twice a day. The designs of these two trials were intentionally similar except that the primary endpoints differed (progression-free survival) in the European Organisation for Research and Treatment of Cancer (EORTC) trial [85] in Australasia and overall survival in the US National Cancer Institute (NCI) trial [86]. The toxicity profile of imatinib is generally better than that of traditional chemotherapy. Fluid retention, diarrhoea, nausea, fatigue, muscle cramps, abdominal pain, and rash are the most common nonhematologic toxicities reported in clinical trials [87]. The side-effect profile may improve with prolonged therapy. A study that reviewed common toxicities noted that 13% of patients suffered grade 3 or higher anaemia and 7% had severe neutropenia. About a third of patients had grade 2 or higher oedema, or fatigue, about a fifth had nausea or diarrhoea, and a sixth had moderate skin rash. Toxicity was generally dose-related and risk factors included advanced age and female gender, possibly related to decrease imatinib clearance in these patient groups. A risk calculator is available for assessing individual patient's risk of imatinib toxicity [88]. Serious side effects (e.g. lung toxicity) were seen in fewer than 5% of patients. Recent reports suggest that concomitant administration of steroids in patients with LFT (liver function test) abnormalities may allow patients to receive imatinib therapy [89]. Patients with large bulky tumours may have a 5% risk of tumour haemorrhage unrelated to thrombocytopenia. These patients should be monitored closely for evidence of a decline in haemoglobin in the first 4 to 8 weeks of imatinib therapy. Asymptomatic bleeding should be monitored closely while treatment with imatinib is continued. However, acute large decreases in haemoglobin of more than 3 g/dL may require temporary withholding of imatinib until haemoglobin has stabilized or until transfusion if patients are symptomatic. Surgical intervention should be considered if bleeding does not resolve. Emergency surgery may also be required in patients with other complications (bowel obstruction, abscess). Patients on long-term imatinib may develop anaemia that may be multifactorial (iron deficiency, chronic disease, B12 deficiency, folate deficiency, suppression of haematopoiesis by the TKI) [29].

Further studies are needed to evaluate the incidence and risk factors of mental depression in patients treated with imatinib. Although symptoms improved with dose reduction or interruption, the response to antidepressants was not consistent. Patients should undergo routine screening for depressive symptoms and suicidal ideations [29].

One of the questions addressed by the CSTIB2222 trial of imatinib therapy for advanced GIST was whether there is a relationship between target kinase mutations and tumour response. Corless and colleagues proposed that GISTs be classified according to their molecular context and provides a quick reference for other syndromes it may be associated with (Table 2) [26].

Few treatment options remain for patients with metastatic or unresectable gastrointestinal stromal tumours (GIST) after objective progression under treatment with approved tyrosine-kinase inhibitors. Kang and colleagues are attempting to evaluate the efficacy of imatinib rechallenge in these patients. "Resumption of imatinib to control metastatic or unresectable gastrointestinal stromal tumours after failure of imatinib and sunitinib (RIGHT): a randomised, placebo-controlled, phase 3 trial." This study is registered with ClinicalTrials.gov, number NCT01151852 [90].

To the extent that the proposed classification may be used to identify patients in whom initial imatinib therapy is likely to fail and kindreds with possible germline KIT mutations, an increase in mutation screening in newly diagnosed GISTs may be expected.

Responses in experimental systems

The clinical results reported above are mirrored by cellular models of imatinib sensitive GIST. KIT-mutant GIST cell lines derived from human tumour specimens typically retain substantial sensitivity to the inhibitory effects of imatinib on KIT kinase activity, unless they are subjected to carcinogen-induced mutagenesis. Imatinib treatment of these cell lines induces a strong anti-proliferative effect, leading some cells to undergo apoptosis through a mechanism that is dependent on histone gamma H2AX, highlighting the requirement for oncogenic KIT signalling, a phenomenon that is often referred to as oncogene addiction [91]. However, many cells simply become quiescent through nuclear p27-mediated exit from the cell cycle, as well as by upregulation of autophagy. Even after prolonged exposure, the removal of imatinib from the culture system allows the cells to resume proliferation [92].

However, it is also possible to induce apoptosis in quiescent GIST cells by using imatinib-synergistic treatments such as ABT-737 (a BCL-2 inhibitor) or RNA interference directed against the pro-apoptotic BCL-2 family member, BIM [93]. In addition, inhibition of the autophagy survival pathway by small interfering (siRNA) against ATG7 or ATG12, or chloroquine inhibition of lysosomal acidification, can also induce apoptosis in GIST cells that are quiescent during imatinib treatment [92]. These data suggest that some form of combination therapy may improve the ability of current TKIs to kill GIST cells. Therefore, TKI therapy can control the growth and survival of differentiated GIST cells that account for most of the cellular make-up of clinical GIST lesions, but this therapy may not control or eradicate the GIST stem and progenitor cell pool [94].

Table 2 Molecular classification of GIST [26].

<i>GIST Type</i>	<i>Comments</i>
Sporadic GIST	
KIT mutation	
Exon 11	Best response to imatinib
Exon 9	Intermediate response to imatinib
Exon 13	Sensitive to imatinib in vitro; clinical responses observed
Exon 17	Sensitive to imatinib in vitro; clinical responses observed
PDGFRA mutation	
Exon 12	Sensitive to imatinib in vitro; clinical responses observed
Exon 18	D842V has poor response to imatinib; other mutations are sensitive
Wild type	Poor response to imatinib
Familial GIST	
KIT exon 11 (V559A, delV559, W557R)	Skin pigmentation, urticaria pigmentosa, mastocytosis
KIT exon 13 (K642E)	No skin pigmentation or mastocytosis
KIT exon 17 (D820Y)	No skin pigmentation or mastocytosis; abnormalities in oesophageal peristalsis
GIST with paraganglioma	Autosomal dominant; endocrine symptoms common
Paediatric GIST	
Sporadic	KIT mutations much less frequent than in adults
Carney's triad	Gastric GIST with pulmonary chondroma and/or paraganglioma; female or male ratio = 7:1; no KIT mutations identified

Imatinib resistance

Approximately 10-15% of patients with GISTs develop primary resistance, which is defined as progression within the first 6 months of treatment [95]. One of the interesting observations that emerged from the Phase II trials, and which was later confirmed in the Phase III trials, is that tumour response to imatinib correlates with the underlying kinase genotype. The probability of primary resistance to imatinib for KIT exon 11, exon 9 and wild-type GISTs is 5%, 16% and 23%, respectively [39, 96]. The most common PDGFRA mutation in GISTs, D842V, is strongly resistant to the effects of imatinib [34]. This mutation favours the active conformation of the kinase domain and consequently disfavours imatinib binding [50, 97]. This has been corroborated by clinical results, since patients with PDGFRA D842V-mutant GISTs have low response rates and very short progression-free and overall survival under imatinib treatment. Wild-type GISTs include tumours with mutations downstream of KIT [54, 56], hence these subsets of wild-type GISTs might respond better to other targeted agents, such as VEGFR inhibitors for paediatric or SDH-mutant GIST, and BRAF or MEK inhibitors for BRAF-mutant GISTs [98].

After an initial benefit from imatinib, the majority of patients develop disease progression or secondary resistance. The resistance may become manifest in various ways, including growth of a nodule within a pre-

existing, clinically quiescent lesion, the development of one or more new nodules, or widespread expansion of lesions throughout the liver or abdominal cavity. It is now established that acquired mutations in KIT or PDGFRA account for most cases of secondary resistance, and that these mutations occur almost exclusively in the same gene and allele as the primary oncogenic driver mutation (Figure 1) [57, 99]. In a Phase II imatinib study for advanced GISTs, 67% of the patients whose tumour showed imatinib resistance had a new, or secondary, mutation in KIT. Secondary mutations of KIT have not been reported in wild-type GISTs, suggesting that KIT activation is not the primary driver of tumour growth in these cases [99]. Unlike primary mutations that activate KIT, which are predominantly in the juxtamembrane regions encoded by exons 9 and 11, the secondary mutations were concentrated in two regions of the KIT kinase domain, which is the domain targeted by imatinib [32, 49, 57, 99].

Drug resistance has also been observed in PDGFRA-mutant GISTs, the most common being an acquired D842V mutation (activation loop) [99]. However, there have been no reliable reports of a secondary KIT mutation arising in a GIST with a primary PDGFRA mutation, or vice versa, under treatment with imatinib. Additional studies using more sensitive assays have identified secondary mutations in more than 80% of drug-resistant GIST lesions [49].

Although secondary mutations in KIT are the most common cause of acquired resistance to imatinib therapy, there are other potential causes of GIST growth in the face of TKI therapy. For example, there can be downregulation or loss of KIT expression associated with a marked increase in cyclin D1 and JUN levels [4]. Over expression of IGF1R has been shown in GISTs lacking primary KIT or PDGFRA mutations, and the inhibition of IGF1R may kill GIST cells independently of KIT mutation status [58]. Focal adhesion kinase (FAK) may also have a role in the growth and survival of imatinib-resistant GIST cells [100].

Alternative targeted therapies for GIST

Unfortunately, most patients will not respond to imatinib dose escalation, forcing a switch to an alternative KIT and PDGFRA TKI. Inhibitors such salvage agents include sunitinib, sorafenib, vatalanib, masitinib, nilotinib and dasatinib, as well as other investigational inhibitors (Table 3). Although all of these agents are KIT and PDGFRA inhibitors, most of them, in contrast to imatinib, also target VEGFR1 and VEGFR2 [101], hence these agents have the potential to control tumour growth by inhibition of angiogenesis, as well as by direct inhibition of KIT and PDGFRA.

Table 3 New therapies being tested for the treatment of GISTs.

Drug	Targets	Trail information
Tyrosine kinase inhibitors		
Imatinib	KIT and PDGFRA	FDA approved
Sunitinib	KIT, PDGFRA and VEGFR	FDA approved
Nilotinib	KIT and PDGFRA	Phase III (ClinicalTrials.gov ID: NCT 00785785)
Dasatanib	KIT and PDGFRA	Phase II (NCT00568750)
Sorafenib	KIT, PDGFRA and VEGFR	Phase II (NCT01091207)
Regorafenib	KIT, PDGFRA and VEGFR	Phase III (NCT01271712)
Vatalanib	KIT, PDGFRA and VEGFR	Phase II (NCT00117299)
Masitinib (AB1010)	KIT and PDGFRA	Phase III (NCT00812240)
Pazopanib	KIT, PDGFRA and VEGFR	Phase II (NCT01323400)
Crenolanib	PDGFRA	Phase II (NCT01243346)
HSP90 inhibitors		
STA-9090	HSP90	Phase II (NCT01039519)
AT-13387	HSP90	Phase II (NCT01294202)
AUY922	HSP90	Phase II (NCT01404650)
Monoclonal antibodies		
IMC-3G3 (Olaratumab)	PDGFRA	Phase II (NCT01316263)
Bevacizumab	VEGFR	Phase III (NCT00324987)
mTOR inhibitor		
Everolimus	mTOR	Phase II (NCT00510354)
Other		
Perisine	AKT (PI3K pathway)	Phase II (NCT00455559)

Abbreviations: FDA= US Food and drug Administration; GISTs= gastrointestinal stromal tumours; HSP90= heat shock protein 90; PDGFRA= platelet-derived growth factor receptor- α ; VEGFR= vascular endothelial growth factor receptor [4].

Sunitinib is US Food and Drug Administration (FDA)-approved for the treatment of patients with GISTs with progression under imatinib but biochemical evidence suggests that the range of activity of sunitinib against secondary imatinib-resistant kinase mutations is suboptimal [102].

Nilotinib, a second-generation selective TKI, is a drug that is structurally similar to imatinib that has limited activity against mutations in domains of ATP-binding pocket or activation loop, and therefore display minimal efficacy in imatinib-resistant cells. Correspondingly, nilotinib has shown limited activity in patients with imatinib-resistant

GISTs in Phase II clinical trial, whereas a sorafenib analogue (regorafenib) provided a remarkable 10-month median progression-free survival, prompting Phase III trial currently underway [103].

Even with newer drugs such as regorafenib (FDA-approved), resistance develops over time, suggesting that escape from ATP-competitive inhibitors of KIT and PDGFRA is inevitable. Interestingly, a new class of non-ATP mimetic kinase inhibitors (known as switch pocket kinase inhibitors, such as DP-2976) have shown high potency when tested in vitro against imatinib-resistant KIT mutants [99, 104]. This class of drug, which suppresses the conformational switch to the activated form of KIT, represents a novel alternative in the battle against TKI resistance.

There is evidence that the PI3K-mTOR signalling pathway is one of the most important pathways in the growth of GIST cells, and multiple medications targeting this pathway are in clinical development. There are also ongoing efforts to test HSP90 inhibitors in the treatment of TKI-resistant GISTs (Table 3) [105]. In theory, an inhibitor “cocktail” could not only prevent secondary resistance from emerging, but might also knock out GIST stem cells and thereby eradicate the disease. However, it can be challenging to combine small-molecule inhibitors for simultaneous treatment, as many of these drugs are metabolized by shared cytochrome P450 pathways (for example, CYP3A4). In particular, combining drugs that inhibit or induce pathways responsible for the metabolism of a co-administered drug can be difficult, if not impossible [105].

Conclusions

Achievements in the treatment of GISTs during the past decade are the direct result of a growing understanding of their molecular biology involved. Although the current recommendations for assessing the risk of progression of a newly diagnosed primary GIST are based on three simple parameters: tumour size, tumour location and mitotic index (mitoses count per mm²), the accuracy of prognoses is likely to be enhanced by incorporating the determination of the mutational status of GISTs [2-4].

The median survival after the diagnosis GIST increased from 19 months to 4.8 years with imatinib treatment. Imatinib has also been proven to improve overall survival and reduce the risk of relapse in localized GIST at high risk of relapse after resection. Sunitinib and regorafenib were drugs also approved by the FDA and EMA. The high frequency KIT and PDGFRA mutations in these tumours makes them sensitive to kinase inhibitors such as imatinib or sunitinib, but resistance develops in most cases. An immediate research goal is to develop new agents that can inhibit the secondary activation loop mutations that confer cross-resistance to all clinically available TKIs.

In addition, the development of effective combination therapy is likely to improve tumour control. To date, our therapeutic approach to GISTs is focused on gain-of-function kinase mutations, but ongoing high-throughput genomic studies are likely to identify additional drivers and modifiers of GIST biology that can be targeted.

Acknowledgements

We are indebted to Marc Chodkiewicz for careful editing of this article. This work was supported by ARC (Association pour la Recherche sur le Cancer) research grant to PdSB. This study was supported by the SIRIC Montpellier Cancer (Grant INCa-DGOS-Inserm 6045) and by the Cancéropôle du Grand Sud-Ouest (Grant INCa-Cancéropôle GSO) to FB. IH was supported by a studentship of the French Ministry of Foreign Affairs and by an IGA studentship of Palacky University, Olomouc.

Conflict of interest

All the authors declare that they have no conflict of interest.

References

- [1] Miettinen M, Lasota J (2001) Gastrointestinal stromal tumors--definition, clinical, histological, immunohistochemical, and molecular genetic features and differential diagnosis. *Virchows Arch* 438:1-12.
- [2] Miettinen M, Lasota J (2006) Gastrointestinal stromal tumors: review on morphology, molecular pathology, prognosis, and differential diagnosis. *Arch Pathol Lab Med* 130:1466-1478.
- [3] Liegl-Atzwanger B, Fletcher JA, Fletcher CD (2010) Gastrointestinal stromal tumors. *Virchows Arch* 456:111-127.
- [4] Corless CL, Barnett CM, Heinrich MC (2011) Gastrointestinal stromal tumours: origin and molecular oncology. *Nat Rev Cancer* 11:865-878.
- [5] Kindblom LG, Remotti HE, Aldenborg F, Meis-Kindblom JM (1998) Gastrointestinal pacemaker cell tumor (GIPACT): gastrointestinal stromal tumors show phenotypic characteristics of the interstitial cells of Cajal. *Am J Pathol* 152:1259-1269.
- [6] Golden T, Stout AP (1941) Smooth muscle tumours of the gastrointestinal tract and retroperitoneal tissues. *Surg Gynecol Obstet* 73:784-790.
- [7] Stout AP (1962) Bizarre smooth muscle tumors of the stomach. *Cancer* 15:400-409.
- [8] Appelman HD (1986) Smooth muscle tumors of the gastrointestinal tract. What we know now that Stout didn't know. *Am J Surg Pathol* 10:83-99.
- [9] Welsh RA, Meyer AT (1969) Ultrastructure of gastric leiomyoma. *Arch Pathol* 87:71-81. [PubMed]
- [10] Franquemont DW (1995) Differentiation and risk assessment of gastrointestinal stromal tumors. *Am J Clin Pathol* 103:41-47.
- [11] Ricci A Jr, Ciccarelli O, Cartun RW, Newcomb P (1987) A clinicopathologic and immunohistochemical study of 16 patients with small intestinal leiomyosarcoma. Limited utility of immunophenotyping. *Cancer* 60:1790-1799.
- [12] Mazur MT, Clark HB (1983) Gastric stromal tumors. Reappraisal of histogenesis. *Am J Surg Pathol* 7:507-519.
- [13] Miettinen M, Virolainen M, Maarit-Sarlomo-Rikala (1995) Gastrointestinal stromal tumors--value of CD34 antigen in their identification and separation from true leiomyomas and schwannomas. *Am J Surg Pathol* 19:207-216.
- [14] Hirota S, Isozaki K, Moriyama Y, Hashimoto K, Nishida T, et al. (1998) Gain-of-function mutations of c-kit in human gastrointestinal stromal tumors. *Science* 279:577-580.

- [15] Miettinen M, Lasota J (2006) Gastrointestinal stromal tumors: review on morphology, molecular pathology, prognosis, and differential diagnosis. *Arch Pathol Lab Med* 130:1466–1478.
- [16] Heinrich MC, Corless CL, Duensing A, McGreevey L, Chen CJ, et al. (2003) PDGFRA activating mutations in gastrointestinal stromal tumors. *Science* 299:708–710.
- [17] Corless CL (2004) Assessing the prognosis of gastrointestinal stromal tumors: a growing role for molecular testing. *Am J Clin Pathol* 122:11–13.
- [18] Fletcher CD, Berman JJ, Corless C, Gorstein F, Lasota J, et al. (2002) Diagnosis of gastrointestinal stromal tumors: A consensus approach. *Hum Pathol* 33:459–465.
- [19] Nilsson B, Bümming P, Meis-Kindblom JM, Odén A, Dortok, et al. (2005) Gastrointestinal stromal tumors: the incidence, prevalence, clinical course, and prognostication in the preimatinib mesylate era—a population-based study in western Sweden. *Cancer* 103:821–329.
- [20] Tryggvason G, Gíslason HG, Magnússon MK, Jónasson JG (2005) Gastrointestinal stromal tumors in Iceland, 1990-2003: the icelandic GIST study, a population-based incidence and pathologic risk stratification study. *Int J Cancer* 117:289–293.
- [21] Miettinen M, Sobin LH, Lasota J. (2005) Gastrointestinal stromal tumors of the stomach: a clinicopathologic, immunohistochemical, and molecular genetic study of 1765 cases with long-term follow-up. *Am J Surg Pathol* 29:52–68.
- [22] Stamatakis M, Douzinas E, Stefanaki C, Safioleas P, Polyzou E, et al. (2009) Gastrointestinal stromal tumor. *World J Surg Oncol* 7:61. doi: 10.1186/1477-7819-7-61.
- [23] Ueyama T, Guo KJ, Hashimoto H, Daimaru Y, Enjoji M (1992) A clinicopathologic and immunohistochemical study of gastrointestinal stromal tumors. *Cancer* 69:947–955.
- [24] Agaimy A, Märkl B, Arnholdt H, Wünsch PH, Terracciano LM, et al. (2009) Multiple sporadic gastrointestinal stromal tumours arising at different gastrointestinal sites: pattern of involvement of the muscularis propria as a clue to independent primary GISTs. *Virchows Arch* 455:101–108.
- [25] Coindre JM, Emile JF, Monges G, Ranchère-Vince D, Scazec JY (2005) Gastrointestinal stromal tumors: definition, histological, immunohistochemical, and molecular features, and diagnostic strategy. *Ann Pathol* 25:358–385.
- [26] Corless CL, Fletcher JA, Heinrich MC (2004) Biology of gastrointestinal stromal tumors. *J Clin Oncol* 22:3813–3825.
- [27] Suster S, Fletcher CD (1996) Gastrointestinal stromal tumors with prominent signet-ring cell features. *Mod Pathol* 9:609–613.
- [28] Sarlomo-Rikala M, Kovatich AJ, Barusevicius A, Miettinen M (1998) CD117: a sensitive marker for gastrointestinal stromal tumors that is more specific than CD34. *Mod Pathol* 11:728–734.
- [29] Demetri GD, von Mehren M, Antonescu CR, DeMatteo RP, Ganjoo KN, et al. (2010) NCCN Task Force report: update on the management of patients with gastrointestinal stromal tumors. *J Natl Compr Canc Netw* 8:S1-S41.
- [30] West RB, Corless CL, Chen X, Rubin BP, Subramanian S, et al. (2004) The novel marker, DOG1, is expressed ubiquitously in gastrointestinal stromal tumors irrespective of KIT or PDGFRA mutation status. *Am J Pathol* 165:107–113.
- [31] Miettinen M, Wang ZF, Lasota J (2009) DOG1 antibody in the differential diagnosis of gastrointestinal stromal tumors: a study of 1840 cases. *Am J Surg Pathol* 33:1401–1408. doi: 10.1097/PAS.0b013e3181a90e1a.
- [32] Hapkova I, Skarda J, Rouleau C, Thys A, Notarnicola C, et al. (2013) High expression of the RNA-binding protein RBPMS2 in gastrointestinal stromal tumors. *Exp Mol Pathol* 94:314–321.
- [33] Medeiros F, Corless CL, Duensing A, Hornick JL, Oliveira AM, et al. (2004) KIT-negative gastrointestinal stromal tumors: proof of concept and therapeutic implications. *Am J Surg Pathol* 28:889–894.
- [34] Corless CL, Schroeder A, Griffith D, Town A, McGreevey L, et al. (2005) PDGFRA mutations in gastrointestinal stromal tumors: frequency, spectrum and in vitro sensitivity to imatinib. *J Clin Oncol* 23:5357–5364.
- [35] Peterson MR, Piao Z, Weidner N, Yi ES (2006) Strong PDGFRA positivity is seen in GISTs but not in other intra-abdominal mesenchymal tumors: Immunohistochemical and mutational analyses. *Appl Immunohistochem Mol Morphol* 14:390–396.
- [36] Agaram NP, Wong GC, Guo T, Maki RG, Singer S, et al. (2008) Novel V600E BRAF mutations in imatinib-naive and imatinib-resistant gastrointestinal stromal tumors. *Genes Chromosomes Cancer* 47:853–859.
- [37] Yan BM, Kaplan GG, Urbanski S, Nash CL, Beck PL (2008) Epidemiology of gastrointestinal stromal tumors in a defined Canadian Health Region: a population-based study. *Int J Surg Pathol* 16:241–250.
- [38] Miettinen M, Lasota J, Sobin LH (2005) Gastrointestinal stromal tumors of the stomach in children and young adults: a clinicopathologic, immunohistochemical, and molecular genetic study of 44 cases with long-term follow-up and review of the literature. *Am J Surg Pathol* 29:1373–1381.
- [39] Heinrich MC, Maki RG, Corless CL, Antonescu CR, Harlow A (2008) Primary and secondary kinase genotypes correlate with the biological and clinical activity of sunitinib in imatinib-resistant gastrointestinal stromal tumor. *J Clin Oncol* 26:5352–5359.
- [40] Blume-Jensen P, Hunter T (2001) Oncogenic kinase signalling. *Nature* 411:355–365.
- [41] Lemmon MA, Schlessinger J (2010) Cell signaling by receptor tyrosine kinases. *Cell* 141:1117–1134.
- [42] Stenman G, Eriksson A, Claesson-Welsh L (1989) Human PDGFA receptor gene maps to the same region on chromosome 4 as the KIT oncogene. *Genes Chromosomes Cancer* 1:155–158.
- [43] Hanks SK, Quinn AM, Hunter T (1988) The protein kinase family: conserved features and deduced phylogeny of the catalytic domains. *Science* 241:42–52.
- [44] Tarn C, Merkel E, Canutescu AA, Shen W, Skorobogatko Y, et al. (2005) Analysis of KIT mutations in sporadic and familial gastrointestinal stromal tumors: therapeutic implications through protein modeling. *Clin Cancer Res* 11:3668–3677.
- [45] Yuzawa S, Opatowsky Y, Zhang Z, Mandiyan V, Lax I, et al. (2007) Structural basis for activation of the receptor tyrosine kinase KIT by stem cell factor. *Cell* 130:323–334.
- [46] Mol CD, Dougan DR, Schneider TR, Skene RJ, Kraus ML, et al. (2004) Structural basis for the autoinhibition and STI-571 inhibition of c-Kit tyrosine kinase. *J Biol Chem* 279:31655–31663.
- [47] Wardelmann E, Losen I, Hans V, Neidt I, Speidel N, et al. (2003) Deletion of Trp-557 and Lys-558 in the juxtamembrane domain of the c-kit protooncogene is associated with metastatic behavior of gastrointestinal stromal tumors. *Int J Cancer* 106:887–895.
- [48] Lasota J, Corless CL, Heinrich MC, Debiec-Rychter M, Sciot R, et al. (2008) Clinicopathologic profile of gastrointestinal stromal tumors (GISTs) with primary KIT exon 13 or exon 17 mutations: a multicenter study on 54 cases. *Mod Pathol* 21:476–484.
- [49] Liegl B, Kepten I, Le C, Zhu M, Demetri G et al. (2008) Heterogeneity of kinase inhibitor resistance mechanisms in GIST. *J Pathol* 216:64–74.
- [50] Gajiwala KS, Wu JC, Christensen J, Deshmukh GD, Diehl W, et al. (2009) KIT kinase mutants show unique mechanisms of drug resistance to imatinib and sunitinib in gastrointestinal stromal tumor patients. *Proc Natl Acad Sci U S A* 106:1542–1747.
- [51] Heldin CH (1992) Structural and functional studies on platelet-derived growth factor. *EMBO J* 11:4251–4259.
- [52] Kawagishi J, Kumabe T, Yoshimoto T, Yamamoto T (1995) Structure, organization, and transcription units of the human alpha-platelet-derived growth factor receptor gene, PDGFRA. *Genomics* 30:224–232.
- [53] Kurahashi M, Zheng H, Dwyer L, Ward SM, Don Koh S, et al. (2011) A functional role for the 'fibroblast-like cells' in gastrointestinal smooth muscles. *J Physiol* 589:697–710.
- [54] Hostein I, Faur N, Primois C, Boury F, Denard J, et al. (2010) BRAF mutation status in gastrointestinal stromal tumors. *Am J Clin Pathol* 133:141–148.
- [55] Stratakis CA, Carney JA (2009) The triad of paragangliomas, gastric stromal tumours and pulmonary chondromas (Carney triad), and the dyad of paragangliomas and gastric stromal

- sarcomas (Carney-Stratakis syndrome): molecular genetics and clinical implications. *J Intern Med* 266:43-52.
- [56] Janeway KA, Kim SY, Lodish M, Nosé V, Rustin P, et al. (2011) Defects in succinate dehydrogenase in gastrointestinal stromal tumors lacking KIT and PDGFRA mutations. *Proc Natl Acad Sci U S A* 108:314-318.
- [57] Antonescu CR, Viale A, Sarran L, Tschernyavsky SJ, Gonen M, et al. (2004) Gene expression in gastrointestinal stromal tumors is distinguished by KIT genotype and anatomic site. *Clin Cancer Res* 10:3282-3290.
- [58] Corless CL, Beadling C, Justusson E, Heinrich MC (2009) Evaluation of the presence of IGF1R overexpression in wild-type and kinase mutant GI stromal tumors. *J Clin Oncol* 27:10506.
- [59] Miettinen M, Fetsch JF, Sobin LH, Lasota J (2006) Gastrointestinal stromal tumors in patients with neurofibromatosis 1: a clinicopathologic and molecular genetic study of 45 cases. *Am J Surg Pathol* 30:90-96.
- [60] Agaram NP, Laquaglia MP, Ustun B, Guo T, Wong GC, et al. (2008) Molecular characterization of pediatric gastrointestinal stromal tumors. *Clin Cancer Res* 14:3204-3215.
- [61] Wozniak A, Sciort R, Guillo L, Pauwels P, Wasag B, et al. (2007) Array CGH analysis in primary gastrointestinal stromal tumors: cytogenetic profile correlates with anatomic site and tumor aggressiveness, irrespective of mutational status. *Genes Chromosomes Cancer* 46:261-276.
- [62] Ylipää A, Hunt KK, Yang J, Lazar AJ, Torres KE, et al. (2011) Integrative genomic characterization and a genomic staging system for gastrointestinal stromal tumors. *Cancer* 117:380-389
- [63] Deneubourg L, Ralea S, Gromova P, Parsons R, Vanderwinden JM, et al. (2011) Abnormal elevated PTEN expression in the mouse antrum of a model of GIST Kit(K641E/K641E). *Cell Signal* 23:1857-1868.
- [64] Taguchi T, Sonobe H, Toyonaga S, Yamasaki I, Shuin T, et al. (2002) Conventional and molecular cytogenetic characterization of a new human cell line, GIST-T1, established from gastrointestinal stromal tumor. *Lab Invest* 82:663-665.
- [65] Bauer S, Yu LK, Demetri GD, Fletcher JA (2006) Heat shock protein 90 inhibition in imatinib-resistant gastrointestinal stromal tumor. *Cancer Res* 66:9153-9161.
- [66] Heinrich MC, Griffith D, McKinley A, Patterson J, Presnell A, et al. (2012) Crenolanib inhibits the drug-resistant PDGFRA D842V mutation associated with imatinib-resistant gastrointestinal stromal tumors. *Clin Cancer Res* 18:4375-4384.
- [67] Rubin BP, Antonescu CR, Scott-Browne JP, Comstock ML, Gu Y, et al. (2005) A knock-in mouse model of gastrointestinal stromal tumor harboring kit K641E. *Cancer Res* 65:6631-6639.
- [68] Bernex F, De Sepulveda P, Kress C, Elbaz C, Delouis C, et al. (1996) Spatial and temporal patterns of c-kit-expressing cells in *WlacZ/+* and *WlacZ/WlacZ* mouse embryos. *Development* 122:3023-3033.
- [69] Sommer G, Agosti V, Ehlers I, Rossi F, Corbacioglu S, et al. (2003) Gastrointestinal stromal tumors in a mouse model by targeted mutation of the Kit receptor tyrosine kinase. *Proc Natl Acad Sci U S A* 100:6706-6711.
- [70] Olson LE, Soriano P (2009) Increased PDGFR α activation disrupts connective tissue development and drives systemic fibrosis. *Dev Cell* 16:303-313.
- [71] Fujimoto H, Shibutani M, Kuroiwa K, Inoue K, Woo GH, et al. (2006) A case report of a spontaneous gastrointestinal stromal tumor (GIST) occurring in a F344 rat. *Toxicol Pathol* 34:164-167.
- [72] Maas CP, ter Haar G, van der Gaag I, Kirpensteijn J (2007) Reclassification of small intestinal and cecal smooth muscle tumors in 72 dogs: clinical, histologic, and immunohistochemical evaluation. *Vet Surg* 36:302-313.
- [73] Hafner S, Harmon BG, King T (2001) Gastrointestinal stromal tumors of the equine cecum. *Vet Pathol* 38:242-246.
- [74] Velarde R, Mentaberre G, Sánchez J, Marco I, Lavín S (2008) KIT-positive gastrointestinal stromal tumours in two Spanish ibex (*Capra pyrenaica hispanica*). *Vet J* 177:445-447.
- [75] Saturday GA, Lasota J, Frost D, Brasky KB, Hubbard G, et al. (2005) KIT-positive gastrointestinal stromal tumor in a 22-year-old male chimpanzee (*Pan troglodites*). *Vet Pathol* 42:362-365.
- [76] Ng EH, Pollock RE, Munsell MF, Atkinson EN, Romsdahl MM (1992) Prognostic factors influencing survival in gastrointestinal leiomyosarcomas. Implications for surgical management and staging. *Ann Surg* 215:68-77.
- [77] Blay JY, Le Cesne A, Cassier PA, Ray-Coquard IL (2012) Gastrointestinal stromal tumors (GIST): a rare entity, a tumor model for personalized therapy, and yet ten different molecular subtypes. *Discov Med* 13:357-367.
- [78] Mauro MJ, O'Dwyer M, Heinrich MC, Druker BJ (2002) STI571: a paradigm of new agents for cancer therapeutics. *J Clin Oncol* 20:325-334.
- [79] Heinrich MC, Griffith DJ, Druker BJ, Wait CL, Ott KA, et al. (2000) Inhibition of c-kit receptor tyrosine kinase activity by STI 571, a selective tyrosine kinase inhibitor. *Blood* 96:925-932.
- [80] Tuveson DA, Willis NA, Jacks T, Griffin JD, Singer S, et al. (2001) STI571 inactivation of the gastrointestinal stromal tumor c-KIT oncoprotein: biological and clinical implications. *Oncogene* 20:5054-5058.
- [81] Joensuu H, Roberts PJ, Sarlomo-Rikala M, Andersson LC, Tervahartiala P, et al. (2001) Effect of the tyrosine kinase inhibitor STI571 in a patient with a metastatic gastrointestinal stromal tumor. *N Engl J Med* 344:1052-1056.
- [82] Goerres GW, Stupp R, Barghouth G, Hany TF, Pestalozzi B, et al. (2005) The value of PET, CT and in-line PET/CT in patients with gastrointestinal stromal tumours: long-term outcome of treatment with imatinib mesylate. *Eur J Nucl Med Mol Imaging* 32:153-162.
- [83] Banzo I, Quirce R, Martínez-Rodríguez I, Jiménez-Bonilla JF, Sainz-Esteban A, et al. (2008) 18F-FDG PET/CT in response evaluation of gastrointestinal stromal tumours treated with imatinib. *Rev Esp Med Nucl* 27:168-175.
- [84] Treglia G, Mirk P, Stefanelli A, Rufini V, Giordano A, et al. (2012) 18F-Fluorodeoxyglucose positron emission tomography in evaluating treatment response to imatinib or other drugs in gastrointestinal stromal tumors: a systematic review. *Clin Imaging* 36:167-175. doi: 10.1016/j.clinimag.2011.08.012.
- [85] Benjamin RS, Rankin C, Fletcher C, Blanke C, Von Mehren M, et al. (2003) Phase III dose-randomized study of imatinib mesylate (STI571) for GIST: Intergroup S0033 early results. *Proc Am Soc Clin Oncol* 22:814.
- [86] Verweij J, Casali PG, Zalcberg J, LeCesne A, Reichardt P, et al. (2004) Progression-free survival in gastrointestinal stromal tumours with high-dose imatinib: randomised trial. *Lancet* 364:1127-1134.
- [87] Guilhot F (2004) Indications for imatinib mesylate therapy and clinical management. *Oncologist* 9:271-281.
- [88] Van Glabbeke M, Verweij J, Casali PG, Simes J, Le Cesne A, et al. (2006) Predicting toxicities for patients with advanced gastrointestinal stromal tumours treated with imatinib: a study of the European Organisation for Research and Treatment of Cancer, the Italian Sarcoma Group, and the Australasian Gastro-Intestinal Trials Group (EORTC-ISG-AGITG). *Eur J Cancer* 42:2277-2285.
- [89] Ferrero D, Pogliani EM, Rege-Cambrin G, Fava C, Mattioli G, et al. (2006) Corticosteroids can reverse severe imatinib-induced hepatotoxicity. *Haematologica* 91:ECR27.
- [90] Kang YK, Ryu MH, Yoo C, Ryoo BY, Kim HJ, et al. (2013) Resumption of imatinib to control metastatic or unresectable gastrointestinal stromal tumours after failure of imatinib and sunitinib (RIGHT): a randomised, placebo-controlled, phase 3 trial. *Lancet Oncol* 14:1175-1182. doi: 10.1016/S1470-2045(13)70453-4.
- [91] Liu Y, Tseng M, Perdreau SA, Rossi F, Antonescu C, et al. (2007) Histone H2AX is a mediator of gastrointestinal stromal tumor cell apoptosis following treatment with imatinib mesylate. *Cancer Res* 67:2685-2692.
- [92] Gupta A, Roy S, Lazar AJ, Wang WL, McAuliffe JC, et al. (2010) Autophagy inhibition and antimetabolites promote cell death in gastrointestinal stromal tumor (GIST). *Proc Natl Acad Sci U S A* 107:14333-14338. doi: 10.1073/pnas.1000248107.

- [93] Reynoso D, Nolden LK, Yang D, Dumont SN, Conley AP, et al. (2011) Synergistic induction of apoptosis by the Bcl-2 inhibitor ABT-737 and imatinib mesylate in gastrointestinal stromal tumor cells. *Mol Oncol* 5:93-104. doi: 10.1016/j.molonc.2010.10.003.
- [94] Bardsley MR, Horváth VJ, Asuzu DT, Lorincz A, Redelman D, et al. (2010) Kitlow stem cells cause resistance to Kit/platelet-derived growth factor alpha inhibitors in murine gastrointestinal stromal tumors. *Gastroenterology* 139:942-952. doi: 10.1053/j.gastro.2010.05.083.
- [95] Gramza AW, Corless CL, Heinrich MC (2009) Resistance to Tyrosine Kinase Inhibitors in Gastrointestinal Stromal Tumors. *Clin Cancer Res* 15:7510-7518.
- [96] Fletcher JA, Corless CL, Dimitrijevic S, Von Mehren M, Eisenberg B, et al. (2003) Mechanisms of resistance to imatinib mesylate (IM) in advanced gastrointestinal stromal tumor (GIST). *Proc Am Soc Clin Oncol* 22:815.
- [97] Biron P, Cassier PA, Fumagalli E, Blesius A, Debiec-Rychter M, et al. (2010) Outcome of patients (pts) with PDGFRAD842V mutant gastrointestinal stromal tumor (GIST) treated with imatinib (IM) for advanced disease. *J Clin Oncol* 25:15s.
- [98] Janeway KA, Albritton KH, Van Den Abbeele AD, D'Amato GZ, Pedrazzoli P, et al. (2009) Sunitinib treatment in pediatric patients with advanced GIST following failure of imatinib. *Pediatr Blood Cancer* 52:767-771. doi: 10.1002/pbc.21909.
- [99] Heinrich MC, Wise S, Hood M, Smith B, Kaufman M, et al. (2010) In vitro activity of novel KIT/PDGFR switch pocket kinase inhibitors against mutations associated with drug-resistant GI stromal tumors. *J Clin Oncol* 28:15s.
- [100] Sakurama K, Noma K, Takaoka M, Tomono Y, Watanabe N, et al. (2009) Inhibition of focal adhesion kinase as a potential therapeutic strategy for imatinib-resistant gastrointestinal stromal tumor. *Mol Cancer Ther* 8:127-134. doi: 10.1158/1535-7163.MCT-08-0884.
- [101] Demetri GD (2011) Differential properties of current tyrosine kinase inhibitors in gastrointestinal stromal tumors. *Semin Oncol* S1:S10-S19. doi: 10.1053/j.seminoncol.2011.01.018.
- [102] Demetri GD, van Oosterom AT, Garrett CR, Blackstein ME, Shah MH, et al. (2006) Efficacy and safety of sunitinib in patients with advanced gastrointestinal stromal tumour after failure of imatinib: a randomised controlled trial. *Lancet* 368:1329-1338.
- [103] George S, von Mehren M, Heinrich MC, Wang Q, Corless CL, et al. (2011) A multicenter phase II study of regorafenib in patients (pts) with advanced gastrointestinal stromal tumor (GIST), after therapy with imatinib (IM) and sunitinib (SU). *J Clin Oncol* 29:10007.
- [104] Eide CA, Adrian LT, Tyner JW, Mac Partlin M, Anderson DJ, et al. (2011) The ABL switch control inhibitor DCC-2036 is active against the chronic myeloid leukemia mutant BCR-ABL T315I and exhibits a narrow resistance profile. *Cancer Res* 71:3189-3195. doi: 10.1158/0008-5472.CAN-10-3224.
- [105] Schöffski P, Reichardt P, Blay JY, Dumez H, Morgan JA, et al. (2010) A phase I-II study of everolimus (RAD001) in combination with imatinib in patients with imatinib-resistant gastrointestinal stromal tumors. *Ann Oncol* 21:1990-1998. doi: 10.1093/annonc/mdq076.